

# TELEHEALTH AS A TOOL IN THE LOCAL SETTING

**Dr Nirav Patel**


**Chris Hani Baragwanath Academic Hospital  
Surgeons For Little Lives**



UNIVERSITY OF THE  
WITWATERSRAND,  
JOHANNESBURG



# BACKGROUND



- Specialist services concentrated
- Impoverished backgrounds
- Wide spectrum congenital and acquired disease

# BACKGROUND

## Poverty:

- $\frac{1}{3}$  below food poverty line

## Unemployment:

- $\frac{1}{3}$  children live in households with no employed adult

## Inequality:

Poorest quintile spend 30% income on transport

# SERVICE DELIVERY

- **Access (seeking, reaching and receiving)**
- **Service delivery**
- **Goal:**
  - Improve access and quality
  - Appropriate to local situation
  - Sustainable
  - Scalable

# BACKGROUND




## **CHBAH:**

- 2 680-bed central hospital

## **Paediatric Surgery:**

- 12 000 unique patient encounters:
  - 2 500 surgical procedures
  - 2 500 admissions
  - 7000 outpatients

Ok tnks Dr one problem can I come  
next week cause for now I don't HV  
money for transportation if it's ok  
 I can make it on Wednesday or  
u can HV me the ather date

13:29

# HYPOTHESIS

- Telemedicine for post operative follow-up
- Safe
- Acceptable
- Cost effective
- Local environment

# METHODS

- Single institution
- Prospective feasibility study
- 1 January to 31 March 2023
- Research Ethics Committee of the University of the Witwatersrand (M220755)



# OUTCOME VARIABLES

- **Patient Level:**
  - Safety
  - Acceptability
  - Savings
    - Direct – transport
    - Indirect – opportunity cost (time off work)
- **Hospital System:**
  - Clinic days

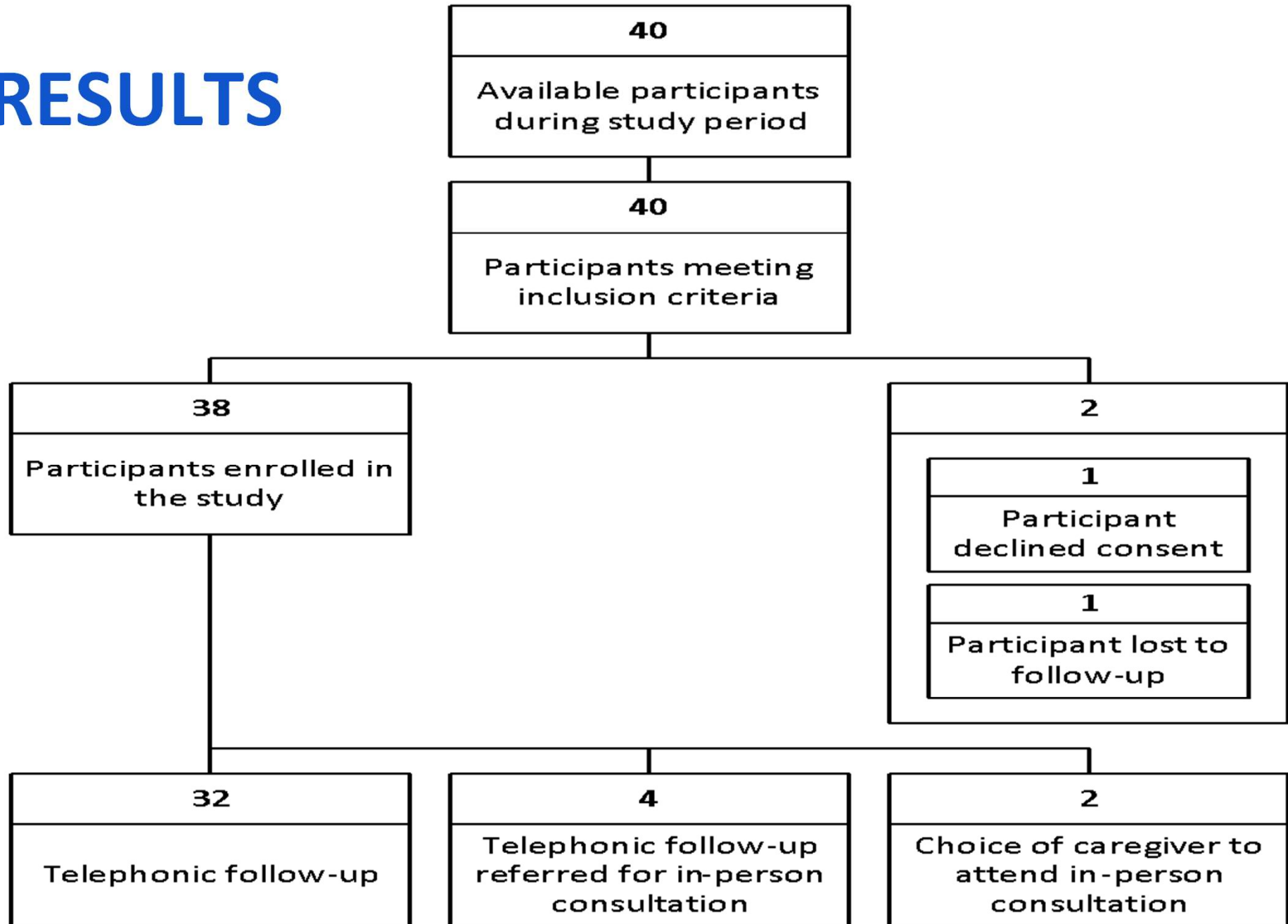
# INCLUSION CRITERIA

- Healthy patients
- < 6 years of age
- Day case surgery:
  - inguinal hernia repair, umbilical hernia repair, surgery for undescended testicle/s, circumcision, chemoport removal, and excision biopsy of a benign mass
- English-speaking guardian (>18 years)
- Smartphone

# PROTOCOL

- **Preoperative conversation:**
  - Post operative wound care
  - Signs/symptoms of complications
- **Telephonic follow-up 1 week post operatively:**
  - Follow up after surgery:
    - Danger signs/symptoms
    - Photographic review of wound
    - Further management
  - Research-related questions:
    - Satisfaction with telephonic follow-up

# RESULTS

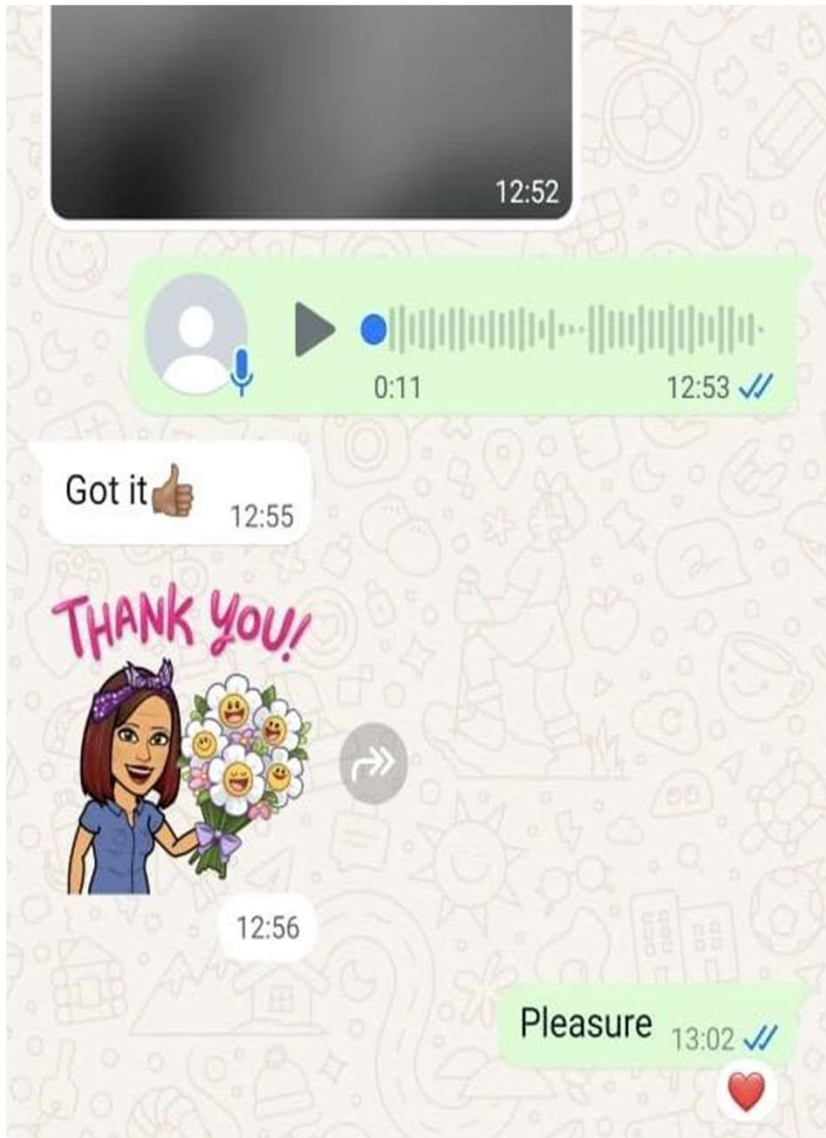


# RESULTS: SAFETY

## 6 in-person review:

- 2 major complications
- 2 minor complications
- 2 parental concerns

# RESULTS: ACCEPTABILITY



- All satisfied
- Utilised service for assistance with unrelated problems

# RESULTS: PATIENT LEVEL SAVINGS

- **Direct transport costs: R4452**
  - R139/person
  - ~ 5 x minimum hourly wage
- **Indirect savings for caregivers**
  - 7 paid leave
  - 2 unpaid leave

# RESULTS:

## PROVIDER AND HOSPITAL LEVEL

### SAVINGS

- 32 clinic visits
- Unknown financial gains
- Time benefit

### COST

- Maximum 2 minutes per call
- Cell charge R500/month
  - Multiple uses



# LIMITATIONS

- Single centre experience
- Limited time frame
- Select patient group

# MOVING FORWARD

- > 530 telephonic follow-ups
- No longer restricted to day case surgery
- 1 person: 1-2 hrs work/week
- ~ 7% OPD patients removed
- Parents at work
- Children in school

# MOVING FORWARD

- Extended to all 3 central hospitals
- Preoperative telephonic consultation

# TELEHEALTH FOR EDUCATION

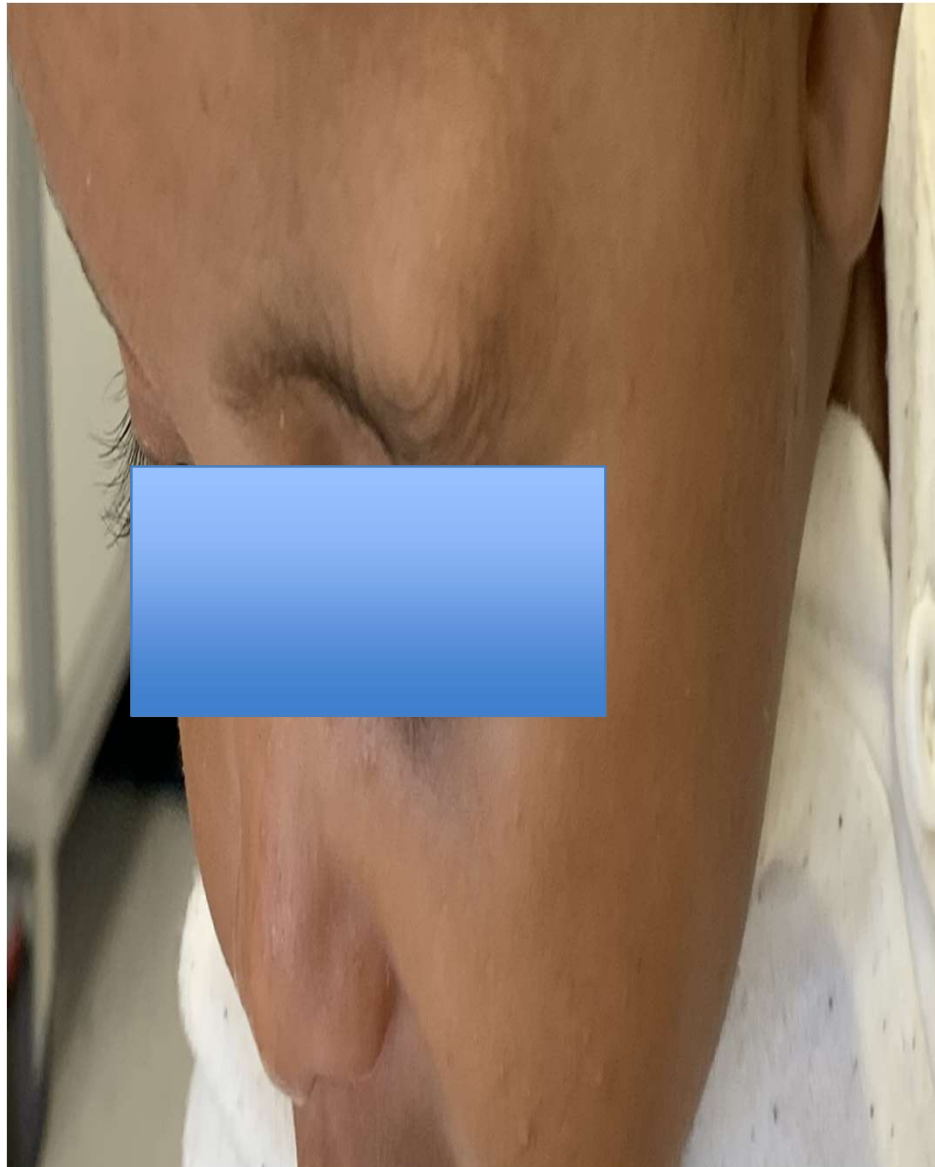History: Right hydrocele ?Inguinal hernia

R TESTIS:	Measured: 14mmx 6mmx 4mm. Normal shape, size and parenchyma. Normal vascularity demonstrated. No obvious masses noted.
R EPIDIDYMIS:	NAD
HYDROCELE:	Hydrocele noted.
L TESTIS :	Measured: 11mmx 6mm x 5mm Normal shape, size and parenchyma. Normal vascularity demonstrated. No obvious masses noted. In the inguinal canal
L EPIDIDYMIS:	NAD
HYDROCELE:	None noted

## CONCLUSION:

- ⇒ Left cryptorchidism: The Left testis was noted in the inguinal canal in the superficial inguinal ring.
- ⇒ Right hydrocele noted.

# TELEHEALTH FOR EDUCATION



Skull 10.38

	3	
	4	
	5	
	6	
	7	
	8	

**Findings:**

There is a small cystic structure in the subcutaneous tissue at the lateral edge of the left eyebrow.

It measures 9.8x3.1mm.

There is no extension intracranially. Appearance of slight thickening of the underlying bone - Not really seen on the skull x-ray.

No overt vascularity seen in lesion

**Comment:**

Finding most likely in keeping with a dermoid cyst.

# IMPROVING BASIC HEALTH EDUCATION

- **Paediatric Surgery for Primary Care in Under 5 Minutes**
- **Common Paediatric Surgical Emergencies in Under 5 Minutes**

# **IMPROVING BASIC HEALTH EDUCATION**

**Paediatric Surgery for Primary Care in Under 5  
Minutes:**

**Inguinal hernia**

**Umbilical hernia**

**Undescended Testes**

**Phimosis**

**Hydrocoele**

# **IMPROVING BASIC HEALTH EDUCATION**

## **Common Paediatric Surgical Emergencies in Under 5 Minutes:**

**Appendicitis**

**Incarcerated inguinal hernia**

**Incarcerated umbilical hernia**

**Intussusception**

**Testicular torsion**





# Discover Paediatric Surgery

@DiscoverPaediatricSurgery

64 subscribers • 9 videos

More about this channel ...more

**Subscribe**

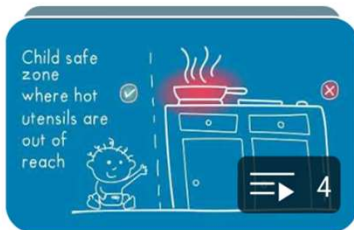Home

Videos

**Playlists**

Search

Date added (newest) ▾



**Burns awareness**

Discover Paediatric Surgery · Playlist



**Paediatric surgery for primary care in under 5 minutes:**

Discover Paediatric Surgery · Playlist




# KnowledgeHub

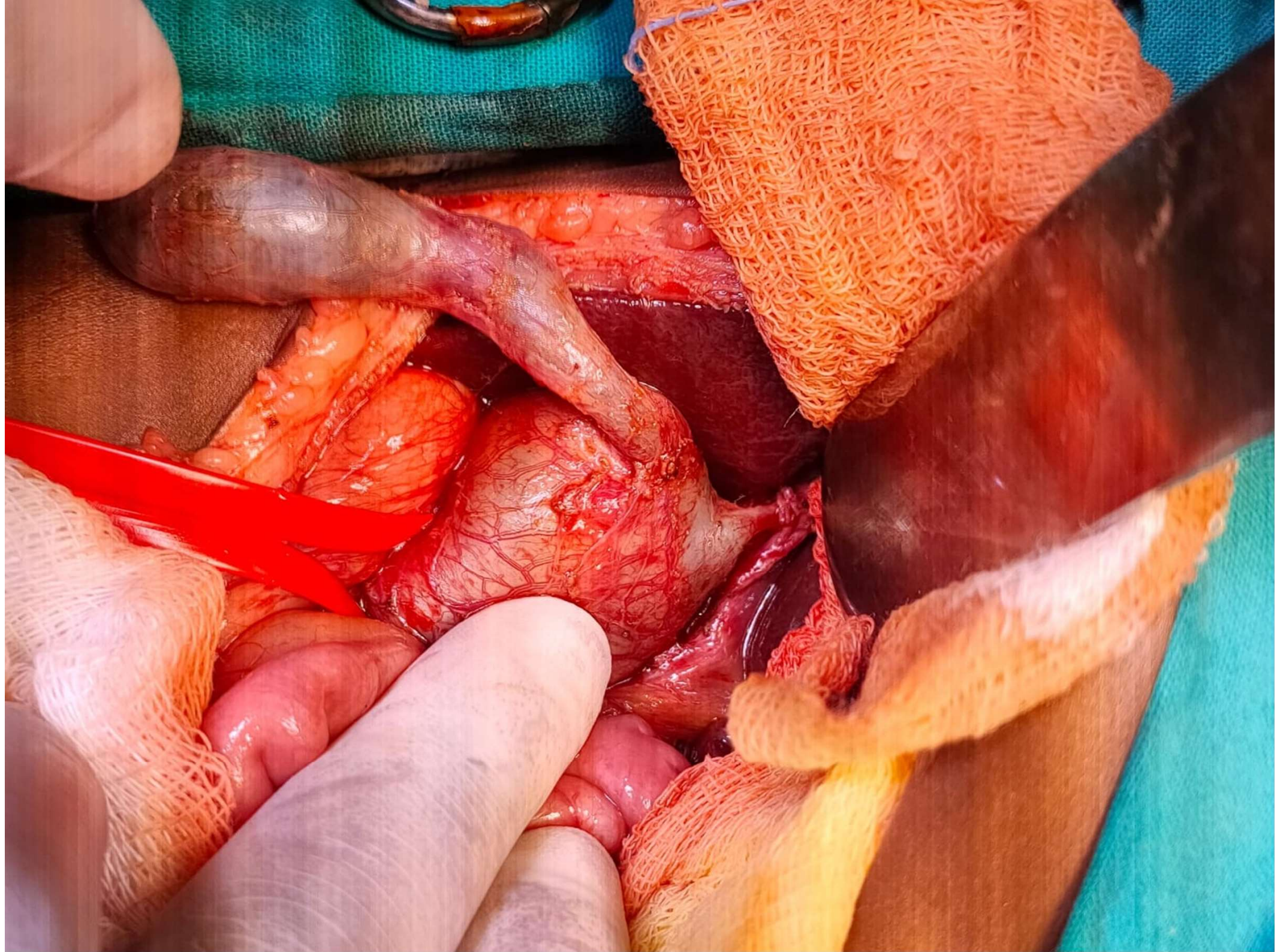
Your Professional Development Platform

# Umbilical hernia in under 5 minutes

A short tutorial for  
Discovery Paediatric Surgery  
by Andrew Grieve, Karen  
Milford, and Nirav Patel.



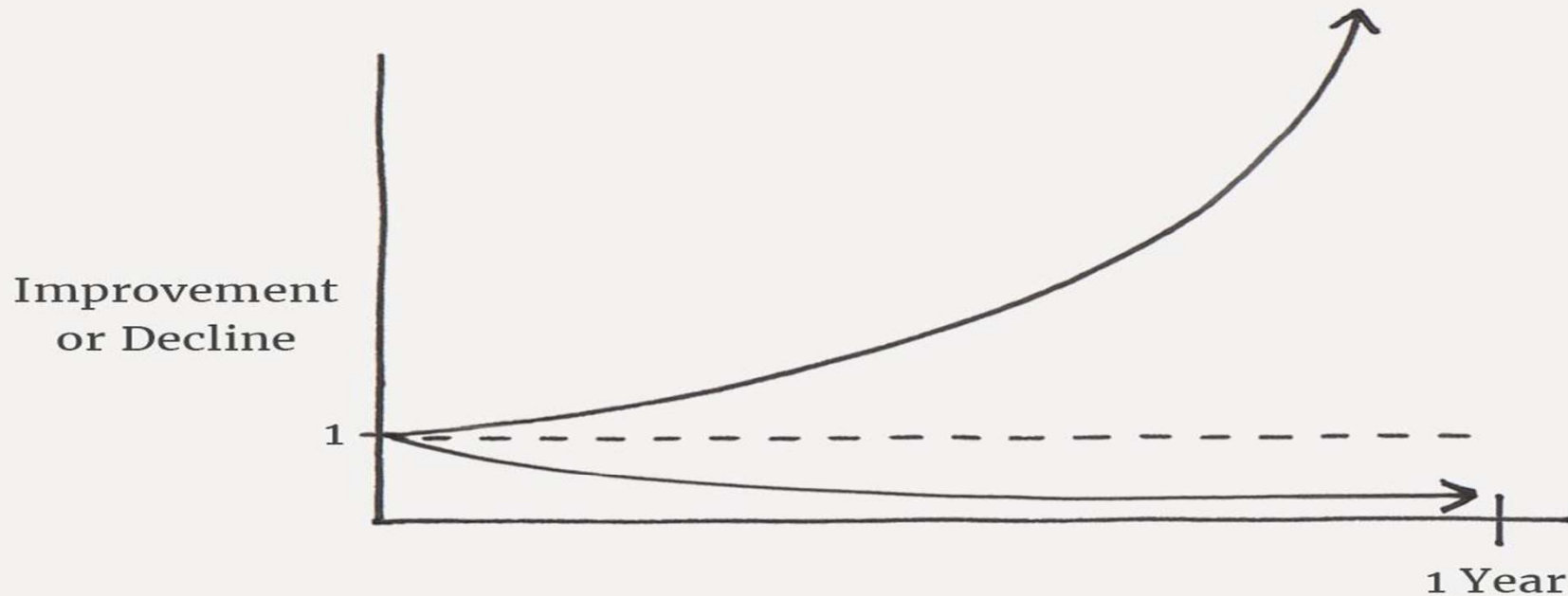
Surgeons for little lives

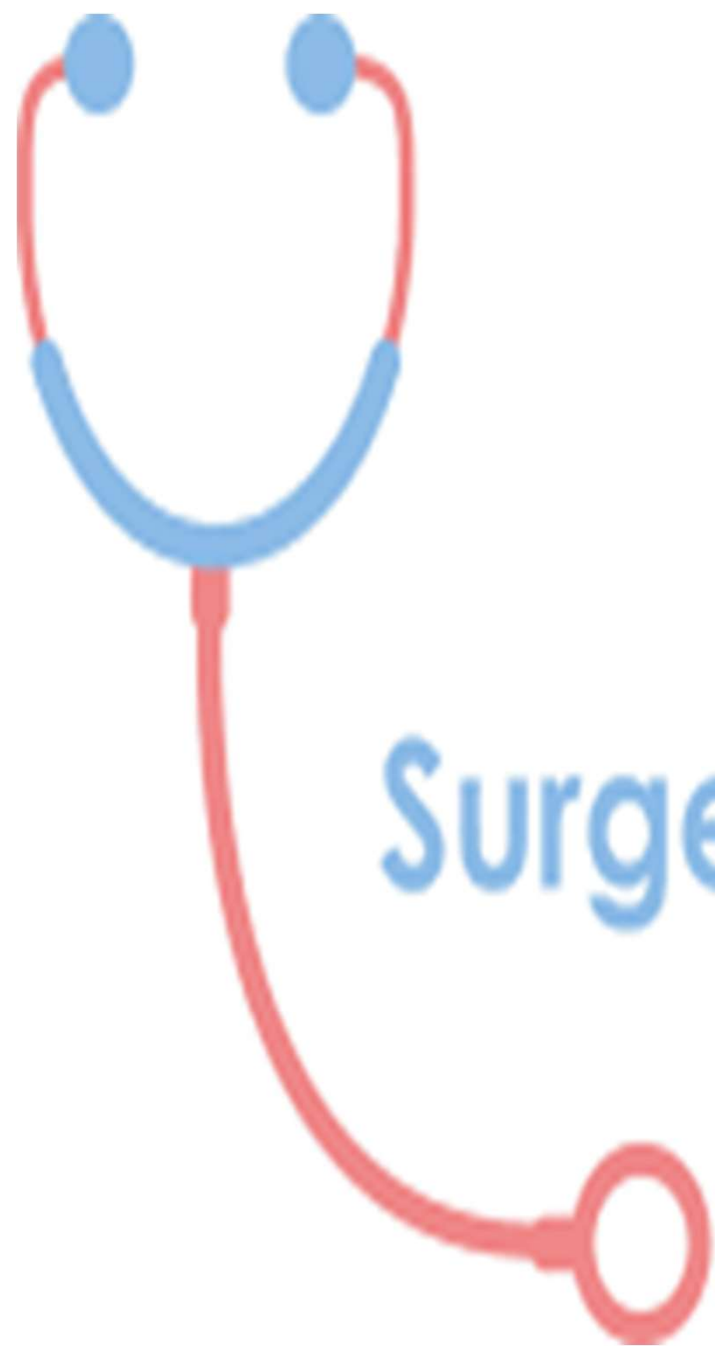



# The Power of Tiny Gains

1% better every day  $1.01^{365} = 37.78$   
1% worse every day  $0.99^{365} = 0.03$





**Surgeons** for little lives